

Series in  
Dermatological  
Treatment

# Acne Scars

Classification and Treatment

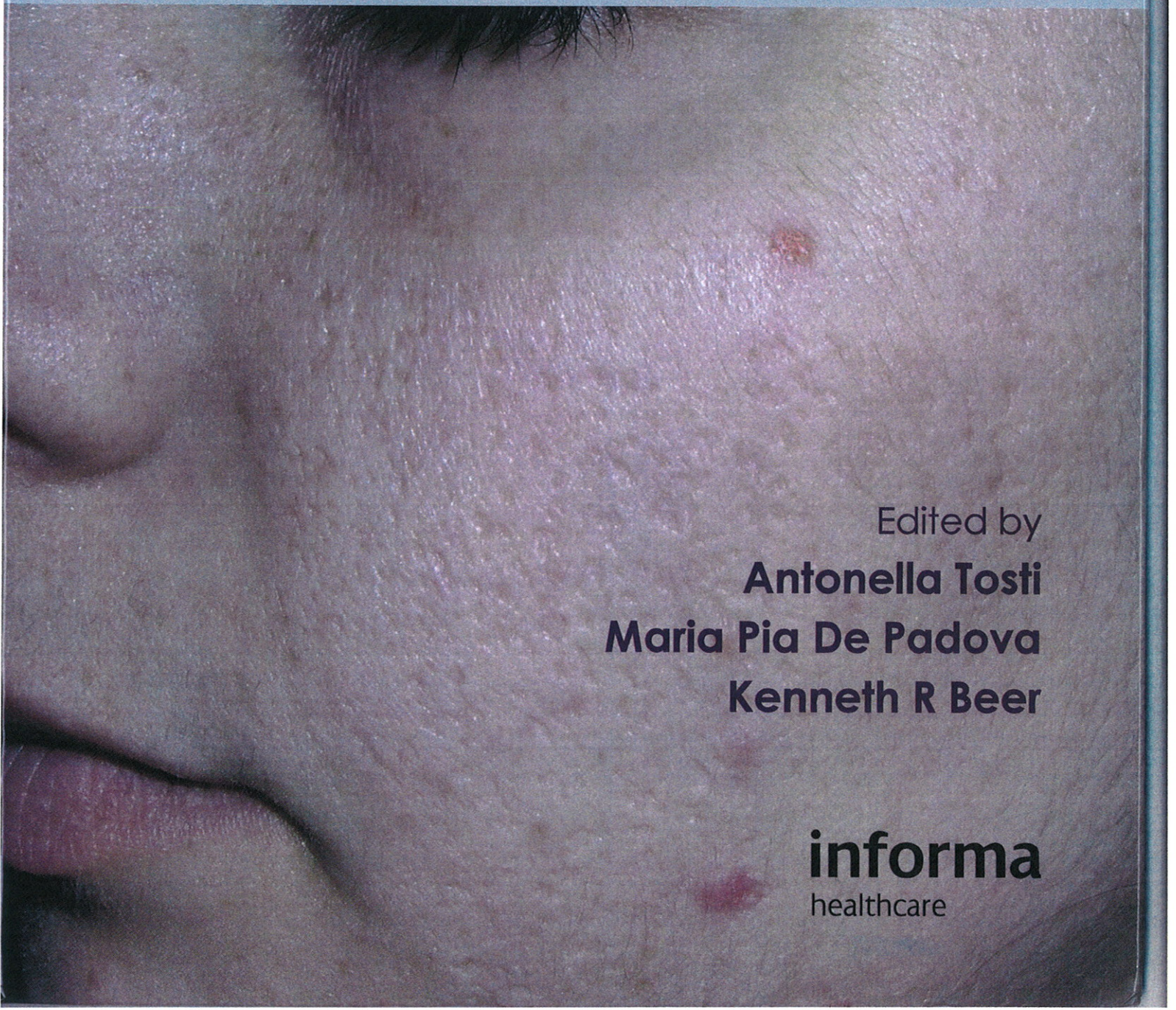
Edited by

**Antonella Tosti**

**Maria Pia De Padova**

**Kenneth R Beer**

**informa**  
healthcare





# 10 Fractional photothermolysis for acne scars

*Kenneth R Beer*

## KEY FEATURES

- Acne scarring is a severe cosmetic concern for many adolescents as well as adults.
- Fractional photothermolysis treats only fractions of the skin.
- Several fractional laser devices are available and each varies as to the type of laser source, treatment settings, spot sizes, and treatment depth.
- The choice of which fractional device should be used is dependent on the type and depth of the scarring as well as the patient's skin type and tolerance for risk.
- Many new laser developments on the horizon including new fractional CO<sub>2</sub> laser systems require no anesthesia and are well tolerated.

## INTRODUCTION

Fractional photothermolysis is a technology developed by Anderson and Manstein that removes fractions of the skin instead of wiping away the entire layer.(1) The benefits of fractional resurfacing include faster recovery time and lower rates of complications compared with traditional laser resurfacing. As with traditional laser resurfacing, different media may be utilized for fractional resurfacing. At the present time, the two most popular media for fractional resurfacing are carbon dioxide (CO<sub>2</sub>) and erbium. Both target water and both vaporize the skin efficiently. The CO<sub>2</sub> laser penetrates to a deeper level than does erbium. These differences in depth of penetration have significant import with respect to the treatment of acne scars. Deeper scars may require the CO<sub>2</sub> fractional laser, while more superficial ones may be amenable to erbium.

Physicians have several options in regards to fractional laser systems, including ablative and non ablative laser systems. The depth and surface area of the scars being treated are the main determinants for system selection and energy settings. Ice-pick and deep acne scars are best treated with a fractional ablative laser able to penetrate deeper into the dermal depths where the abnormal, scarred collagen resides. Superficial scarring may be amenable to treatment with a fractional nonablative device. This less invasive device will improve the patient's appearance (and self-esteem) with less risk and minimal downtime. Additional treatment options for acne scars are available and the risks and benefits compared with fractional photothermolysis should be discussed with each patient prior to engaging in any type of treatment regimen. Chief among the options for the treatment of acne scars are dermabrasion, subcision, cosmetic fillers, chemical acid peels, punch biopsy, and excision.

## ADVANTAGES OF FRACTIONAL LASERS FOR THE TREATMENT OF ACNE SCARS

Fractional photothermolysis offers many advantages when compared with traditional laser treatment of acne scars. Traditional CO<sub>2</sub> lasers were prone to many complications, including scarring, infection, and hyperpigmentation. This combination of sequelae were responsible for the decline in popularity of the procedure. When used for acne scars, the traditional CO<sub>2</sub> laser was able to improve some patient's scarring, but the potential to exacerbate the problem was significant. Traditional erbium lasers had lower rates of complications but were largely ineffective both for cosmetic indications and for the treatment of acne scarring. One publication that evaluated the outcomes of both CO<sub>2</sub> and erbium lasers for the treatment of acne scars concluded that most of the data that had been accumulated was insufficient to allow either patient or physician to conclude the degree to which traditional lasers improved acne scars.(2) Despite some publications and some physicians advocating the use of these lasers for the treatment of acne scars, the lack of data to support these claims led to the abandonment of the procedure for this indication. When these lasers became fractionated, the ability to treat acne scars once again became a subject of interest for physicians and surgeons alike.

## HISTORY OF FRACTIONAL RESURFACING LASERS FOR THE TREATMENT OF ACNE SCARS

Since the technology of fractional thermolysis lasers is relatively new, the history of the use of these devices for this indication is short with few well-controlled clinical trials published prior to the publication of this book. The first publications regarding fractional laser technology came out in 2004 and the use of fractional laser technology for the treatment of acne scars began shortly thereafter.

## A REVIEW OF SOME FRACTIONAL LASER DEVICES AND A REVIEW OF THEIR EFFICACY FOR THE TREATMENT OF ACNE SCARS

There are many different devices that may be utilized to treat acne scars. It is beyond the scope of this chapter to review the myriad devices that are used throughout the world. Instead, a focus will be placed on the systems that are most prevalent at the present time. Although the various manufacturers incorporate different technologies and have differences in their treatment algorithms, some general trends are valid across the various platforms. It will be useful to have an understanding of the present fractional laser devices as indicated for the treatment of acne scars.

The first widely available fractional laser was introduced by Reliant and was known as the Fraxel. A Medline search of



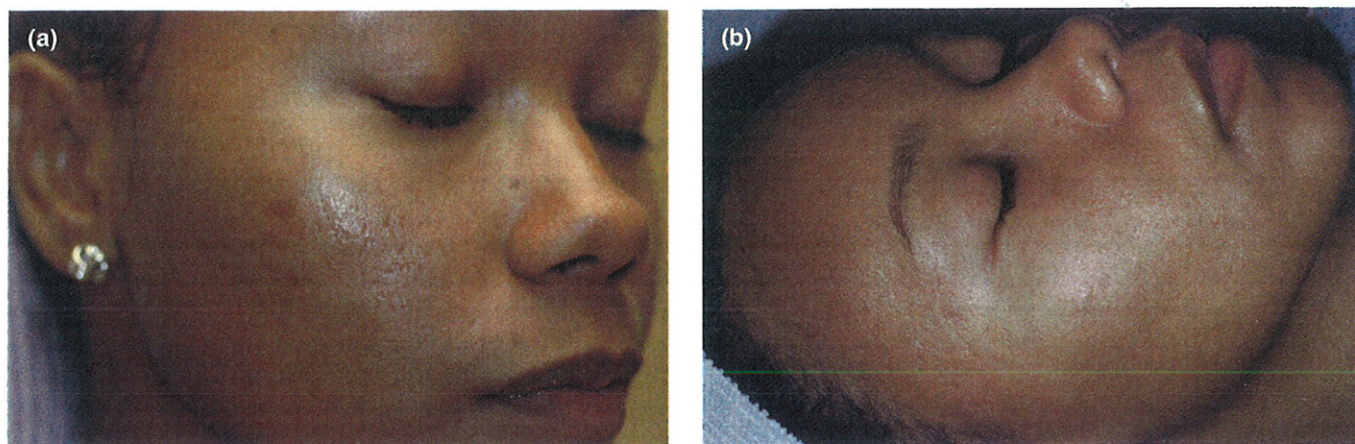


Figure 10.1 (A) Moderate acne scars in a common location, the cheeks. The patient is a type VI skin type. (B) Following three treatments with the Fraxel 1550 laser, the appearance of the scars is improved. There is no evidence of any hyperpigmentation. (Courtesy of Dr. Jill Waibel.)

fractional laser treatment of acne scars reveals that this is also the device that has been most widely used in publications reporting treatment of acne scars with fractional lasers. This device uses an erbium source at a wavelength of 1550.<sup>(3)</sup> Early versions of this required the use of a blue dye to enable the tracking system to scan the areas that had and had not been treated. This was viewed by many as an inconvenience and subsequent devices no longer use this dye. Typical configurations of the Fraxel laser incorporate a chilling device from Zimmer to cool the skin as the laser treats it. This cooling has several functions but the two most relevant ones for the treatment of acne scars is that it enables the patient to tolerate higher energy levels, thereby reaching depths typical of acne scars. A second advantage is theoretical, but it is possible that this chilling protects the bulge portion of the hair follicle enabling the stem cells to repopulate the skin from a deeper (and thus more even) level.

Fraxel lasers enable the physician to alter the depth and density of the beamlets. When treating acne, this ability allows the user to increase the density when it is necessary to ablate more of the surface area and to increase the depth (energy) to treat deeper scars. Whereas other techniques such as dermabrasion and chemical peeling do not enable the physician to match the depth of the treatment to the depth of the acne scar, Fraxel can alter the depth of penetration to precisely accomplish this. Thus, at an energy setting of 20 mJ, the depth of the laser penetration is 794  $\mu$ , while at 40 mJ it is 1120  $\mu$ .<sup>(4)</sup> As with any system, one limitation is that treatments are uncomfortable at high-energy settings so the use of topical or injectional anesthetic is beneficial.

In clinical experience, the Fraxel has been used to treat acne scars with a high degree of patient satisfaction for scars that are relatively small and relatively shallow (Figure 10.1). One study that evaluated the use of the initial model of this laser to treat mild-to-moderate atrophic acne scars in 53 patients concluded

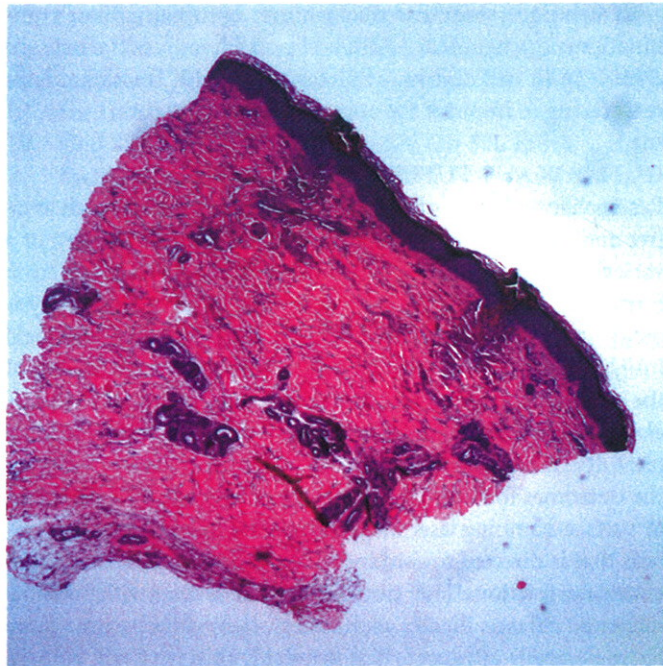
that the treatments were safe and effective.<sup>(5)</sup> Acne scars in this study were treated monthly for 3 months. The authors found that clinical improvements in the range of 51% to 75% were seen in nearly all (90%) of the subjects treated. Few complications were noted. Whether additional treatments would have improved scars to a greater extent or intrinsic collagen remodeling helped diminish the appearance of the scars after the study concluded is not known.

The Fraxel SR model is an improved device that does not require the use of blue dyes to target the laser. This has also been demonstrated to improve the appearance of acne scars. Chrastil et al. evaluated the Fraxel SR for the treatment of acne scars in skin types I-V. The SR model enabled treatments at higher fluences and greater densities than prior models. Fluences used in these patients were between 35–40 mJ/ microthermal zone and the percent of treatment coverage was between 20% and 35%. Following between two and six treatments, the majority of patients had an improvement in the appearance of their acne scars between 50% and 75%.<sup>(6)</sup> These authors also noted no adverse events with the use of this device to treat acne scars.

Many different skin types have been treated with this device in an effort to treat acne scars. Acne scars in types V and VI skin are notoriously difficult to treat with many treatment regimens resulting in hyperpigmentation, hypopigmentation, and keloid formation. Fraxel treatment of 27 patients with types V and VI skin were performed to treat moderate-to-severe acne scars. In these patients, 30% of patients reported excellent improvements, while another 50% reported significant improvement. As with other reports, adverse events were limited to transient issues such as erythema and edema. The authors concluded that fractional resurfacing (Fraxel) was a significantly effective means of treating acne scars in this patient population.<sup>(7)</sup>

One fractional CO<sub>2</sub> laser with the ability to penetrate deeply and treat acne scars is the UltraPulse from Lumenis. This device





*Figure 10.2* Fractional CO<sub>2</sub> laser using the Lumenis Ultrapulse. This biopsy demonstrates the ability of fractional CO<sub>2</sub> lasers to penetrate to the depth of the acne scar as well as its ability to spare the intervening tissue. It is this latter property that enables rapid healing.

has been engineered to deliver higher energy levels than many other devices on the market with peak energy levels of 225 mJ. It combines two different modalities, Deep FX and Active FX, to enable the physician to address superficial and deep acne scars. One characteristic of the device that lends itself to the treatment of acne scars is its limited thermal spread due to its short pulse duration of <1 ms. This device is also able to treat deep scars with the Deep FX hand piece, which penetrates deeper into the skin (Figure 10.2); the Active FX hand piece may be used to treat superficial scarring. This laser also has a large scan pattern size of up to 10 mm × 10 mm, enabling the physician to treat large body surfaces in a relatively short amount of time. This device affords better results as seen with traditional CO<sub>2</sub> lasers with a decreased recovery time and, therefore, increased patient satisfaction. Currently a study is being done to determine the recovery rate of patients treated with the Active FX in comparison with traditional CO<sub>2</sub> resurfacing techniques [h1] [h1] [h1].(8)

Fractional photothermolysis has been used to treat patients who had a combination of mild-to-moderate acne scars combined with enlarged pores.(9) This population is representative of many patients presenting for treatment. The system used for this trial was a Lutronic 1,550 nm erbium glass laser. A total of 12 patients with type V skin were treated with 3 sessions spaced 1 month apart. Improvement was evaluated by a blinded

observer who concluded that 8 patients had improvements of between 51% and 100% in 4 months after the last treatment was performed. Complications seen during the study were limited to treatment related erythema and swelling. No significant hyperpigmentation or scarring was noted. This study was notable for demonstrating histology associated with the treatment, and it is notable for demonstrating isolated microthermal zone damage to the epidermis and collagen. The depth of the injury is comparable to the depth associated with many mild-to-moderate acne scars, and it is possible that this correlation of treatment depth to the underlying pathophysiology of the acne scar is responsible for the high degree of improvement. The depth did not appear to be deep enough to ablate the hair matrix, and this probably is the reason why scarring was avoided. In this study, patient satisfaction was more correlated with improvement of acne scars than with pore size

Fractional photothermolysis lasers are made by many companies. Each device has strengths and weaknesses that have important implications for treating acne scars. Differences in the lasers include different wavelengths, spot sizes, fluence levels, density of laser beamlets, skin cooling systems, and ease of use (for both physician and patient). Another critical difference for the treatment of acne scars is the degree to which the different devices have been used in well-designed clinical trials. As with any indication, it is important to have a reasonable likelihood of success with good patient safety profile.

Slim Evolution Lasering recently developed a microspot system with a fractional modality (Mixto SX). This new function prolongs the time between two adjacent treatment spots. This modality prevents heat from building up around the treated spots, thus significantly reducing pain throughout the treatment. With fractional photothermolysis, some form of topical anesthesia and/or cooling system is needed. With the Mixto SX, the procedure is well tolerated without any anesthesia or skin-cooling system.(10) The Mixto SX laser system also has the traditional single CO<sub>2</sub> laser beam that can be used to remove solid lesions or to make incisions. This setting can be switched with the touch of a button and no need to swap handpieces. Patients with acne scars can be treated with such a laser, and because no anesthesia or cooling is needed, it decreases the time in office.

Palomar also makes a fractional erbium laser. It uses a wavelength of 1,540 nm and also targets water as the chromophore. In addition to these two devices, the Affirm, a 1,440 nm Nd:Yag fractional laser produced by Cynosure (Westford, MA), the ProFractional made by Sciton (Palo Alto, CA), Ultrapulse manufactured by Lumenis (Santa Clara, CA), the Juvia by Ellipse (Atlanta, GA), and many other devices may be used for fractional laser treatments of acne scars. There are many significant differences between the various laser systems. The differences, some subtle others not so subtle, have significant bearing on their use for esthetic rejuvenation in general and the treatment of acne scars in particular.

From the perspective of the physician using the device, the most significant difference between various devices is whether



it is ablative or not. Ablative devices use CO<sub>2</sub> and penetrate to a deeper level than do nonablative systems. The degree of collagen stimulation from the ablative devices will be significantly more compared to that of a nonablative device utilized. For acne scars, deeper and broader scars may be treated effectively with ablative devices capable of resurfacing to a deeper level. More superficial acne scars, requiring less depth for scar correction, need nonablative erbium lasers.

Considerations other than whether a device is ablative or nonablative are also important for treating acne scars. Some machines have scanners that allow the operator to dial in the depth, while some others use energy settings as a proxy for depth. When treating acne scars, it is helpful to have the ability to match the depth of resurfacing to the depth of the scar. Many devices have fixed-spot sizes that are larger than the scars being treated. This requires the user to manually calculate the depth needed.

Whereas the Palomar system has a fixed-spot size that must be manually moved to stamp out the treated areas, the Reliant system uses a handpiece that uses rollers to scan across the skin. This enables the physician to focus on certain locations. In this case, treating acne scars means that instead of treating the areas around the scar, the laser may be used to treat the scar itself and blur the boundaries between it and adjacent, normal skin. Acne scars are notoriously variable in their depth, which is one reason why they are so prominent. The Reliant fractional device enables the user to change the depth of the beam with a great degree of precision so that the laser can approximate the depth of the scar.

CO<sub>2</sub> fractional lasers are also available from Reliant, and these devices may be useful for treating deeper acne scars. These devices deliver a 30 W CO<sub>2</sub> laser light at a wavelength of 10,600 nm. In comparison with nonablative fractional devices, ablative fractionals utilize the same concept of treating only microscopic areas that are then surrounded by healthy untreated skin. With only a portion of the skin treated, the patient will experience less perioperative discomfort and decreased postoperative complications. The novelty of CO<sub>2</sub> fractional laser is that it enables better outcomes as seen with traditional CO<sub>2</sub> lasers, but with less downtime and adverse effects.

According to Zachary et al., acne scarring is most common "on the mid cheek and temple area".(11) Acneiform scars are a result of damage to collagen production in the deep dermal layers.(12) In patients with superficial or moderate acne scars, treatment with fractional lasers may produce dramatic results. However, those with deep, depressed acne scars with sharp borders may not respond well to fractional resurfacing and may require other modalities such as excisions, chemical peels, or a combination of modalities. One interesting possibility is the combined use of fillers such as hyaluronic acid with fractional resurfacing. The hyaluron would lift the deep portion of the scar up and reduce the volume of scar, while the fractional laser would blur the borders of the epidermal components. Several other combinations of fillers (including the use of porcine collagen) with fractional lasers may yield results not obtainable

with technique alone and research into optimizing these combinations is warranted. Additional possible adjuncts discussed elsewhere in this text may be combined with fractional laser resurfacing to improve the appearance of acne scars.

#### OUTLOOK AND FUTURE DEVELOPMENTS

Research into the use of fractional photothermolysis (both ablative and nonablative) is being conducted for the treatment of a variety of scars. Whereas the etiology of scars that result from burns and scars resulting from acne have differing pathophysiology, it is likely that the use of these lasers for each will yield insights into ways to help the other. A better understanding of the molecular biology underlying the remodeling of collagen, elastin, and the epidermis, following treatment with fractional photothermolysis, will indubitably result in means to enhance the outcomes for laser treatments for acne scars. Combinations of surface-scanning laser imaging married to fractional thermolysis that is directed toward individual scars has the potential to customize fractional laser treatments for acne scars with potential increased efficacy. Finally, as the lasers themselves become more technologically advanced, it is inevitable that they will be used for better effect to treat this prevalent and disfiguring problem.

#### SUMMARY FOR THE CLINICIAN

Fractional lasers offer effective treatment for many types of acne scars. They may be used at depths that match the depth of the scars in question.

Both ablative and nonablative lasers have a role in the treatment of acne scars, and choosing between the two requires a knowledge of the differences between them, the depths of the scars, and an understanding of the interaction of these devices with different skin types.

#### REFERENCES

1. Manstein D, Herron GS, Sink RK, Tanner H, Anderson RR. Fractional photothermolysis: a new concept for cutaneous remodeling using microscopic patterns of thermal injury. *Lasers Surg Med* 2004; 34(5): 426–38.
2. Jordan R, Cummins C, Burls A. Laser resurfacing of the skin for the improvement of facial acne scarring: a systematic review of the evidence. *Br J Dermatol* 2000; 142: 413–23.
3. Pubmed accessed on Nov. 22, 2008.
4. Source: Reliant Inc. Hayward CA.
5. Alster T, Tanzi E and Lazarus M. The use of fractional laser photothermolysis for the treatment of atrophic scars. *Dermatol Surg* 2007; 33: 295–9.
6. Chrastil B, Glaich AS, Goldberg LH, Friedman PM. Second generation 1,550 nm fractional photothermolysis for the treatment of acne scars. *Dermatol Surg* 2008; 34(10): 1327–32.
7. Lee HS, Lee JH, Ahn GY et al. Fractional photothermolysis for the treatment of acne scars: a report of 27 Korean Patients. *J Dermatolog Treat* 2008; 19(1): 45–9.

8. Goldberg, David. Reduced Down-time associated with novel fractional ultrapulse CO<sub>2</sub> treatment (ActiveFX) as compared to traditional CO<sub>2</sub> resurfacing. *JAAD* 2007; 56(2): AB206.
9. Cho SB, Lee JH, Choi MJ, Lee KY, Oh SH. Efficacy of the fractional photothermolysis system with dynamic operating mode on acne scars and enlarged pores. *Dermatol Surg* 2009; 35: 108–14.
10. Cassuto D. An innovative device for fractional CO<sub>2</sub> laser resurfacing: a preliminary clinical study. *Am J Cosmet Surg* 2008; 25(2): 97–101.
11. Zachary C, Rokhsar C, Fitzpatrick R. Laser Skin Resurfacing in Goldberg D. *Lasers and Lights Vol II*.
12. Chapas AM, Brightman L, Sukal S et al. Successful treatment of acne scars w/CO<sub>2</sub>. *Lasers Surg Med* 2008; 40(6): 381–6.