

Murad Alam  
Marisa Pongprutthipan  
*Editors*

# Body Rejuvenation

 Springer

# Chapter 1

## Treatment of Platysmal Bands with Botulinum Toxin

Kenneth R. Beer

### Introduction

The use of Botulinum toxins for the upper third of the face has been a well-ensconced facet of dermatologic surgery for over a decade. With greater experience with this toxin, additional areas have been treated with varying degrees of success. The middle third of the face as well as the lower thirds of the face may be injected by physicians with advanced technical abilities and knowledge of the relevant anatomy. Within the lower third of the face, the mentalis and platysma are easily treated with Botulinum toxins. Despite the fact that the platysma is not technically part of the lower third of the face, the muscle functions as a depressor of this region and its treatment greatly impacts the overall aesthetic of the entire face. Its treatment with Botulinum toxins is a relatively simple technique that can be mastered by those with experience in the upper third of the face and it can be extremely rewarding for both patient and physician. Newer modalities of radiofrequency, fractional resurfacing, and laser are able to change the texture and color of the neck. Combining these with injections of botulinum toxins offers the opportunity to dramatically improve an area that has traditionally been recalcitrant to rejuvenation.

### Clinical Examination

The lower third of the face has several depressors that serve to pull it in a caudal direction. These include the depressor anguli oris, depressor labii, the mentalis and, to an extent, the platysma. Inactivation of the depressors will tend to enable the elevator muscles to lift the lower third of the face. When used in conjunction with fillers for this area, the results of these treatments can be dramatic and synergistic. Injections of the platysma

tend to neutralize the downward pull from this muscle and also to affect the appearance of the muscle, which has a dramatic result in many individuals.

As with the rest of the body, platysmal bands change over time. During the first few decades of life, the platysma is camouflaged by a thin layer of subcutaneous fat. In addition, the anatomy of the muscle is that of a diffuse band rather than a group of strings. With age, the layer of fat disappears and there is no barrier between the muscle and the skin. Thus, each string of the muscle can be visualized. Concurrently, the muscle becomes a series of fibrous bands rather than a homogenous layer. The combination of the loss of a barrier layer and development of discrete bands leads itself to treatment with Botulinum toxins.

The platysma is a superficial and diffuse muscle. Its insertion is onto the chin and its origin is on the sternum. It may be best visualized by asking the patient to grimace or make a monster face (Fig. 1.1). Variations in individual anatomy are common and each patient should be assessed and treated according to their anatomy.

One caveat that bears mention is that injections into patients without dynamic contributions from the platysma (e.g., those with flaccid necks that require liposuction or that have redundant skin for which surgery is the only solution) will result in patients who are dissatisfied. As with other Botulinum toxin treatments, proper patient selection is important when injecting the neck.

### Treatment Indications

#### Setting Selection

In comparison with upper facial injections, the dilution of Botulinum toxin for this area may be more diffuse as the muscle itself is diffuse rather than discrete.

**Fig. 1.1** Well defined platysma bands are evident in this 6-year-old girl



When injecting Botox, dilutions between 2 and 4 mL per 100 units, is appropriate. For Dysport, the dilution should be between 2 and 4 mL per 300 units. Dilution with more saline than these amounts may be beneficial for this area since diffusion may help to deactivate this diffuse muscle.

### **Treatment Technique**

Anatomic considerations when injecting the neck are paramount to patient safety. The strap muscles of the neck are adjacent to the thyroid cartilage and errant injection of toxin may potentially interfere with their functions. This may impair the ability to swallow and, in rare instances, necessitate a feeding tube (a suboptimal outcome for a cosmetic patient). If a patient treated in the neck with Botulinum toxin reports difficulty swallowing, immediate consultation with an otorhinolaryngologist for a swallowing study is indicated. Fortunately, this complication is extremely rare.

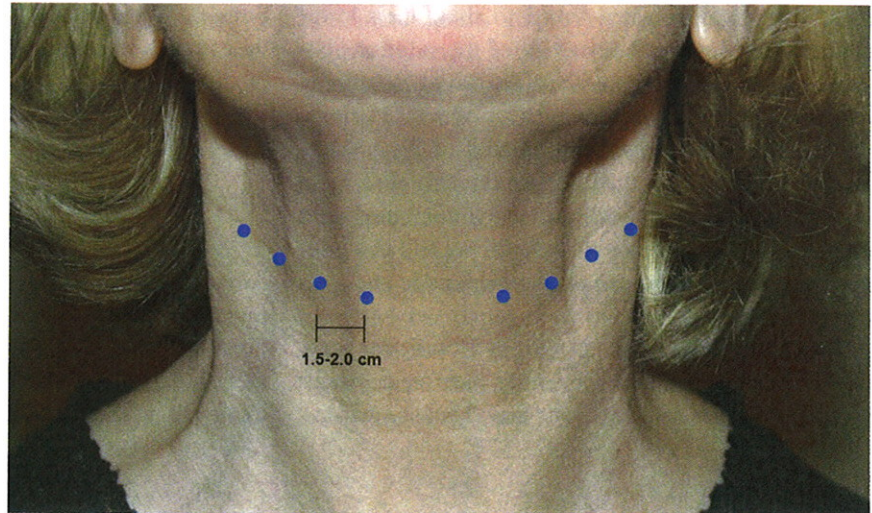
Injection techniques depend on the anatomy being treated. To visualize the platysma and observe the function of the muscle, one needs to activate it by asking the patient to grimace or to show you their lower teeth. In some individuals, the platysma muscle is broad and

drapes out over the span of the neck. Other individuals have vertical muscles that are typically 2–4 bands that can be easily grasped.

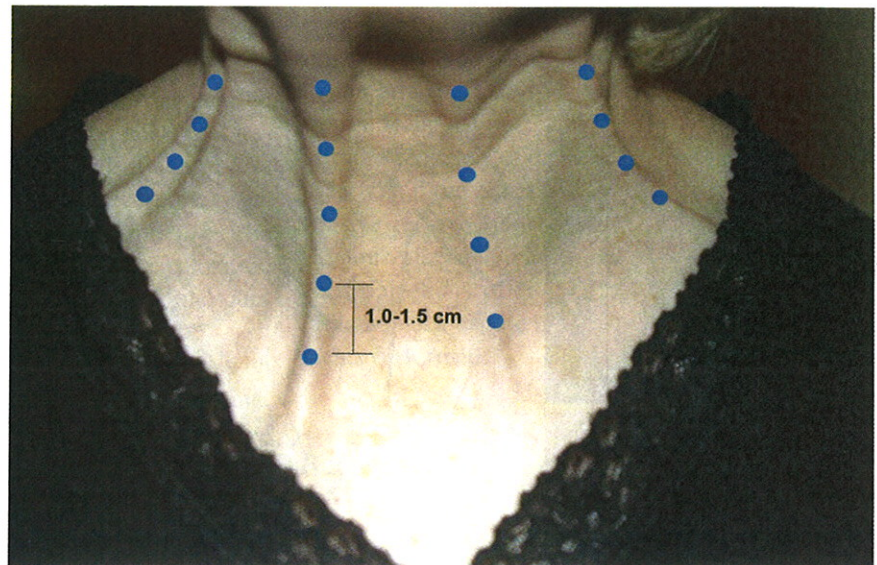
For patients with broad diffuse muscles of the neck, injections should be diffuse and should be spaced out across the area that moves with contraction (Fig. 1.2). Each injection should be approximately 1.5–2 cm apart and it is helpful to inject in a horizontal manner. Subcutaneous injections should be made with the needle in the superficial dermis. Raising a bleb, each area should be injected with about 2.5 units of toxin for Botox or 7.5 units for Dysport. When beginning to treat this area, women may be treated with between 25 and 50 units of Botox or 50–120 units of Dysport depending on their muscle mass. Men require more than this and may be treated with between 30 and 75 units of Botox or 60–180 units of Dysport.

Discrete muscle bands are best injected by grabbing the band and injecting it by putting the needle into the muscle (in contrast with the subcutaneous injections for diffuse platysma) (Fig. 1.3). Injections of 2.5 units of Botox or about 6–8 units of Dysport are made about 1–1.5 cm apart. Total amount of Botox or Dysport injected into patients with discrete bands is about what is used for patients with diffuse bands but many injectors find it helpful to use slightly higher doses directly into the muscles.

**Fig. 1.2** Injection pattern for patients with broad diffuse muscle patterns. Courtesy of Sarah Weitzul, MD



**Fig. 1.3** Injection pattern for patients with discrete muscle bands. Courtesy of Sarah Weitzul, MD



Carruthers and Carruthers have provided an excellent description for the treatment of the platysmal area with Botulinum toxins.<sup>1</sup> They describe the horizontal neck lines that may be seen in younger patients with thick necks. These, they believe, are caused by the superficial musculoaponeurotic bands. In their article, they recommend “dancing” along the neck, injecting 1–2 units of Botox in the deep dermis at intervals of about 1 cm apart. This technique has significant

appeal for patients with this type of anatomy and the referenced article recommends injecting no more than 15–20 units.

The platysma, as it invests the inferior sternum, also gives rise to wrinkles of the décolleté. This area is one of the most frequently cited for cosmetic enhancement. Botulinum toxins have been successfully used to smooth this area.<sup>2</sup> As with other areas, patient selection is paramount. For patients who have

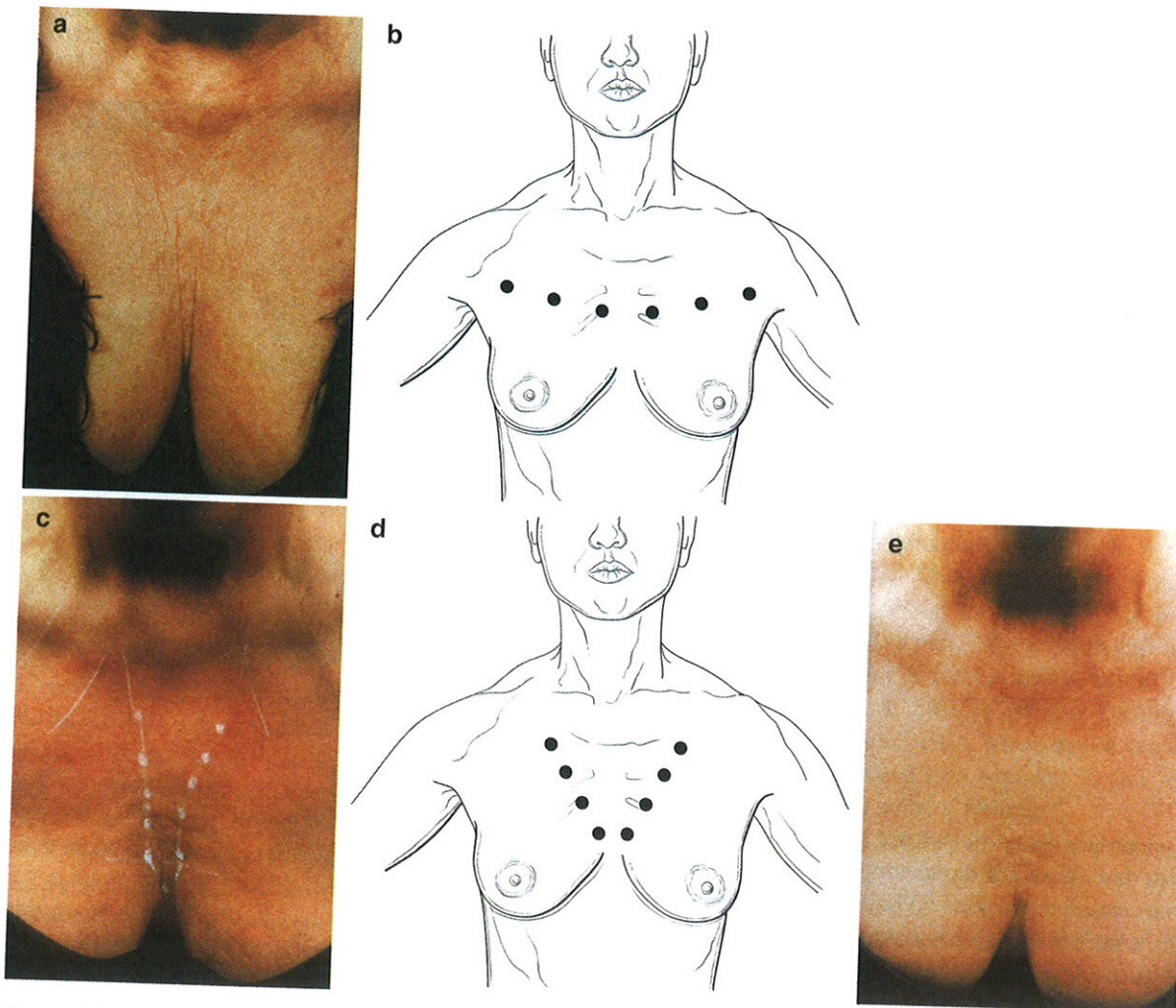
significant rippling when asked to show their lower teeth or to grimace, the activity of the inferior platysma may be dampened with injections of Botulinum toxins. Suggested doses range from 25 to 75 units, depending on the length and breadth of the muscle. Injections should be made approximately 1–1.5 cm apart (Fig. 1.4). The décolleté, when combined with modalities such as fractional resurfacing and photodynamic light treatment, can produce dramatic and gratifying results.

There are several caveats about Botulinum toxin treatments of the platysma. Obviously, there are numerous vascular structures in this area and they should be avoided.

Straying superior or diffusion into the musculature of the lower third of the face can cause asymmetry of the mouth.

### Alternative Treatment Methods

Alternatives to Botulinum treatments for the neck include minimally invasive surgical approaches, traditional surgery, and laser treatments. Perhaps the treatment best suited for those who are not candidates for treatment with toxin because they have loose bands



**Fig. 1.4** (a) Prior to treatment, patient presents with V-shaped wrinkles of the décolleté. (b) Schematic of horizontal injection sites to treat vertical wrinkles. (c) Patient 1 week after horizontal injections. However, patient still presents with horizontal wrinkles of the décolleté. (d) Schematic of vertical injection sites to treat horizontal wrinkles. (e) Patient 1 week after vertical injections

that no longer contract is a modified platysma banding such as that described by Kaminer et al. If this minimally invasive technique is not adequate, traditional rhytidectomy may be performed.

### **Combinations of Botulinum Toxins with Other Modalities**

Treatment of the platysma area may obtain optimal results when combined with other modalities. As lasers and other energy devices become more effective, they may be used to enhance patient outcomes. Among the devices that are potential, synergistic opportunities for treatment with Botulinum toxins are radiofrequency, fractional resurfacing, infrared, and liposuction.

Radiofrequency has been utilized for cosmetic enhancement of the neck with varying degrees of success. Recent advances in the settings used for this treatment and improvements in the tips have enhanced the ability of these devices to treat the neck successfully. When used in conjunction with Botulinum toxins, they may help to create a smoother contour of the neck as the toxins reduce the bands formed by the platysma. This area seems ripe for further exploration as the radiofrequency technology improves and controlled trials in this area would be worthwhile.

A second energy device used in conjunction with Botulinum toxins in the neck is fractional resurfacing. There are several variations of this technology (discussed elsewhere in the book) but each removes small areas of the skin and stimulates collagen formation. They may enhance the appearance of the neck by removing many of the signs of aging from the skin. In conjunction with toxins, this affords the neck a more youthful appearance and the synergy between these techniques is likely to result in increased patient satisfaction. There is documentation that treatments with

Botulinum toxins improves the results from laser resurfacing and it is likely that it will also enhance the outcomes from fractional resurfacing since the mechanism of action is similar.<sup>3</sup>

Liposuction is a minimally invasive technique to reduce the fat in the neck. Following this procedure, the muscular bands may become more prominent. Botulinum toxin may be injected in this scenario to minimize the appearance of these bands, which may have been camouflaged by the adipose. It is likely that many patients undergoing liposuction of the neck will want to have this area treated with Botulinum toxins for optimal outcomes.

### **Conclusion**

Treatments of the lower third of the face and neck with Botulinum toxins may produce significant cosmetic improvements in these areas. Injections of Botulinum toxins into the platysma bands are relatively simple from a technical perspective. Newer modalities, such as radiofrequency and fractional resurfacing, may be used with these injections to produce a more comprehensive rejuvenation of the neck. For patients with dynamic platysmal bands and physicians with experience, injections of Botulinum toxins into the lower face and neck can be one of the most gratifying treatments performed.

### **References**

1. Carruthers A, Carruthers J. Aesthetic Botulinum toxin in the mid and lower face and neck. *Dermatol Surg.* 2003;29:468-476.
2. Becker-Wegerich PM, Rauch L, Ruzicka T. Botulinum toxin A: Successful décolleté rejuvenation. *Dermatol Surg.* 2002;28(2):168-171.
3. West T, Alster T. Effect of Botulinum toxin on following resurfacing. *Dermatol Surg.* 1999;25(4):259-261.